

REVIEW ARTICLE

Allan H. Ropper, M.D., *Editor*

Spontaneous Intracerebral Hemorrhage

Kevin N. Sheth, M.D.

SPONTANEOUS INTRACEREBRAL HEMORRHAGE ACCOUNTS FOR APPROXIMATELY 10 TO 15% OF ALL STROKES.¹ Other disorders that result in bleeding within the cranium, such as traumatic hemorrhage, rupture of cerebral aneurysms or malformations, and hemorrhagic transformation of ischemic stroke, are not discussed in this review except as they relate to the differential diagnosis.

CLINICAL PRESENTATION AND EARLY ASSESSMENT

Patients with intracerebral hemorrhage present with focal neurologic signs that are abrupt in onset but not instantaneous, as occurs with embolic ischemic stroke. The evolution is typically over minutes. Further differentiating hemorrhagic from ischemic stroke are headache, nausea or vomiting, and, in many cases, a depressed level of consciousness. The distinction between hemorrhagic and ischemic stroke is definitively made by imaging, as discussed below. A reduced level of consciousness usually indicates compression of the arousal nuclei and pathways of the upper brain stem; alternatively, intraventricular hemorrhage with hydrocephalus can cause stupor. Hemorrhage in the basal ganglia causes contralateral hemiplegia and a gaze preference to the side of the bleeding owing to transection of the adjacent internal capsule. Thalamic hemorrhage causes hemiplegia for the same reason, along with peculiar eye signs, including downward and inward deviation, miotic pupils, and occasionally “wrong-way eyes,” in which the gaze preference is away from the side of the lesion; in awake patients, hemisensory loss may be detected. Focal neurologic deficits with intracerebral hemorrhage in the cerebral hemispheres (lobar hemorrhage) correspond to the location of the hemorrhage and its transection of white-matter tracts; these deficits include hemiparesis, hemisensory loss, and gaze preference and may simulate ischemic stroke. Hemorrhage in the brain stem is usually located in the pons and causes an impaired level of consciousness, cranial nerve palsies, pinpoint (but reactive) pupils, absent or impaired horizontal gaze, ocular bobbing (a sign in which the eyes rapidly and conjugately deviate downward and then slowly upward to midposition), and facial weakness. Dysarthria may be present in awake patients, but disruption of the reticular activating system in the midbrain and upper pons leads to coma, obviating detection of this sign. Cerebellar intracerebral hemorrhage usually originates in the region of a dentate nucleus deep within the cerebellar hemisphere. Symptoms include vertigo, vomiting, and limb ataxia (dysmetria and particularly gait ataxia), which may be the sole sign and is missed unless the patient is taken off the bed or stretcher and asked to walk. Obstruction of the fourth ventricle by blood that leaks from the brain stem during cerebellar bleeding may lead to hydrocephalus and stupor or coma.

EPIDEMIOLOGY AND RISK FACTORS

Over the past two decades, the annual incidence of intracerebral hemorrhage in the United States has doubled to approximately 80,000 per year, and death from intra-

From the Division of Neurocritical Care and Emergency Neurology, Departments of Neurology and Neurosurgery, and the Yale Center for Brain and Mind Health, Yale School of Medicine, New Haven, CT. Dr. Sheth can be contacted at kevin.sheth@yale.edu or at 15 York St., LLCI Room 1003C, P.O. Box 208018, New Haven, CT 06510.

This article was updated on March 16, 2023, at NEJM.org.

N Engl J Med 2022;387:1589-96.

DOI: 10.1056/NEJMra2201449

Copyright © 2022 Massachusetts Medical Society.

CME
at NEJM.org

cerebral hemorrhage has been estimated to occur in 30 to 40% of cases.² Because most patients who survive intracerebral hemorrhage have disabilities and are at risk for recurrent stroke, cognitive decline, and systemic vascular disorders, this disorder takes on particular importance among neurologic conditions.

The main inciting causes of intracerebral hemorrhage in adults are hypertension, cerebral amyloid angiopathy, and anticoagulation. Older age is associated with an increased frequency of intracerebral hemorrhage, owing in part to the association of advanced age with cerebral amyloid angiopathy and with conditions such as atrial fibrillation that result in exposure to anticoagulation therapy. Over the past several decades, the use of direct oral anticoagulants has reduced, but not eliminated, the risk of intracerebral hemorrhage as compared with the use of vitamin K inhibitors. Improved population-level blood-pressure control has also reduced the incidence of intracerebral hemorrhage.

A meta-analysis of studies that had been performed in 21 countries between 1983 and 2006 showed an overall incidence of intracerebral hemorrhage of 24.6 per 100,000 person-years.³ The risk estimates increased with age and were approximately twice as high in Asian populations as in White populations.³ In the United States, the risk of intracerebral hemorrhage is approximately 1.6 times as high among Black persons and Hispanic persons as among White persons.⁴

Hypertension was the strongest attributable risk factor for intracerebral hemorrhage in most populations that have been studied,⁵ and subgroup analyses from randomized trials of therapies to control blood pressure have shown that lowering blood pressure decreases the incidence of intracerebral hemorrhage. The Perindopril Protection against Recurrent Stroke Study (PROGRESS) and Secondary Prevention of Small Subcortical Strokes (SPS3) trial^{6,7} showed a lower incidence of intracerebral hemorrhage among patients who had a low blood-pressure target for the reduction of overall cardiovascular risk than among patients whose blood-pressure target was higher; however, the absolute numbers of patients with intracerebral hemorrhage were small in these trials. In addition, mendelian randomization studies have shown a link between polygenic risk scores for hypertension and the risk of intracerebral hemorrhage.⁸

PATHOPHYSIOLOGY AND LOCATION OF INTRACEREBRAL HEMORRHAGE

Typical spontaneous intracerebral hemorrhage occurs in deep brain structures as a consequence of damage to the walls of small cerebral blood vessels that traverse these regions. These small arteries and arterioles are in most cases branches of large vessels of the circle of Willis that supply the basal ganglia, thalamus, pons, and deep portions of the cerebellum. Hypertensive cerebral vasculopathy and cerebral amyloid angiopathy preferentially affect vessels of this size.

Intracerebral bleeding has long been attributed to rupture of microaneurysms on small, deep vessels. Findings in pathological specimens have suggested that the pathophysiological mechanism by which hypertension causes putaminal and thalamic hemorrhage is what C.M. Fisher termed “lipohyalinotic change,” a combination of hyalinization and lipid deposition in the vessel wall. His determination that these are sites of vessel rupture and not microaneurysms that also result from chronic hypertension was only apparent after painstaking examination of hundreds of microscopic serial sections.⁹ Investigations in the early parts of the last century implicated these aneurysms (Charcot–Bouchard aneurysms) as the cause of bleeding.

Lobar intracerebral hemorrhage, in which the hematoma is located in the white matter of the frontal, parietal, temporal, or occipital lobe, is more common in recent series than deep intracerebral hemorrhage. Chronic hypertension is also a risk factor for lobar hemorrhage, albeit to a lesser degree than for deep hemorrhage; anticoagulation and rupture of arteriovenous malformations account for a larger proportion of lobar hemorrhages than of basal ganglia hemorrhages.¹⁰ Cerebral amyloid angiopathy is predominantly associated with lobar intracerebral hemorrhage or hemorrhage into the cerebellum and is a result of β -amyloid deposition in arterioles and capillaries emanating from the leptomeninges and cortical vessels.^{11,12} In patients who have received anticoagulant therapy, especially in those with lobar intracerebral hemorrhage attributable to cerebral amyloid angiopathy, the safety of continued anticoagulation is unclear. With regard to both lobar and nonlobar intracerebral hemorrhage, ongoing clinical trials (Anticoagulation in ICH Survivors for Stroke Prevention and Recovery

[ASPIRE; ClinicalTrials.gov number, NCT03907046] and Edoxaban for Intracranial Hemorrhage Survivors with Atrial Fibrillation [ENRICH-AF; NCT03950076]) will evaluate whether the use of new oral coagulants will result in fewer recurrent strokes and with low rates of cerebral hemorrhage as compared with aspirin in the first trial and no treatment in the second trial in patients with atrial fibrillation who have had previous cerebral hemorrhages.

An age older than 60 years and the presence of apolipoprotein (Apo) E2 and ApoE4 are associated with β -amyloid vascular deposition. The ApoE2 and ApoE4 alleles confer a risk for intracerebral hemorrhage that is three to five times that in persons with the more common ApoE3 genotype.^{13,14} In cases of cerebral hemorrhage from amyloid angiopathy, magnetic resonance imaging (MRI) of the brain often reveals multiple (sometimes hundreds of) tiny asymptomatic hemorrhages of different ages, dilated perivascular spaces, and superficial siderosis of the cortex owing to deposition of blood breakdown products from previous episodes of bleeding.¹⁵

In patients with intracerebral hemorrhage, the volume of the clot at the time of hospital admission is a predictor of the functional outcome at 3 months.¹⁶ An increase in volume between the first computed tomography (CT) of the brain after presentation and a second CT (usually performed within 6 to 24 hours after the first CT) occurs in about 25% of spontaneous cases and in 30 to 40% of anticoagulation-associated cases and is likewise predictive of outcome, as discussed below. Hematoma expansion that causes worsening of clinical signs is particularly associated with poor functional outcome at 3 months.¹⁷

Secondary brain injury begins immediately after the primary mechanical injury to brain tissue caused by the clot and by perihematomal edema¹⁸ that is visible on imaging within hours after the intracerebral hemorrhage. Perihematomal edema formation contributes to early neurologic deterioration beyond that caused by the mass of the clot, and these changes can evolve for days. The volume of perihematomal edema varies, but the ultimate edema volume may be as large as the initial hematoma. Every additional milliliter of edema volume can be as much as double the odds of a poor functional outcome.^{19,20}

IMAGING

CT and MRI are sensitive and specific for the diagnosis of acute intracerebral hemorrhage, and they establish the location and volume of the clot (Fig. 1).²¹ As part of the initial imaging evaluation, a CT angiogram may detect an aneurysm or vascular malformation that underlies intracerebral hemorrhage, information that can facilitate the management of treatment; however, these findings are not common if the clot is contained entirely within the brain substance. The guidelines of the American Heart Association regarding intracerebral hemorrhage suggest that CT angiography be performed in patients who are younger than 70 years of age and have lobar intracerebral hemorrhage, in those who are younger than 45 years of age and have deep or posterior fossa intracerebral hemorrhage, and in those who are 45 to 70 years of age and have no history of hypertension.²²

ASSESSMENT SCALES

The American Heart Association recommends early assessment of the severity of intracerebral hemorrhage with the use of one of several validated scales.²² One scale that is commonly used, the Intracerebral Hemorrhage (ICH) score, incorporates the Glasgow Coma Scale score, the patient's age, the presence of infratentorial hemorrhage or intraventricular hemorrhage, and clot volume.²³ The initial ICH score estimates the risk of early death and death at 12 months as well as functional outcome,²⁴ but the primary purpose of the tool is for quality improvement and for use by providers in discussions regarding clinical severity.

TREATMENT OF EARLY DETERIORATION AFTER INTRACEREBRAL HEMORRHAGE

The focus for treatment of patients after an intracerebral hemorrhage is the prevention of secondary brain damage. The elements of secondary damage that have attracted the most attention and that are amenable to treatment are clot enlargement, secondary brain edema, and intraventricular hemorrhage.

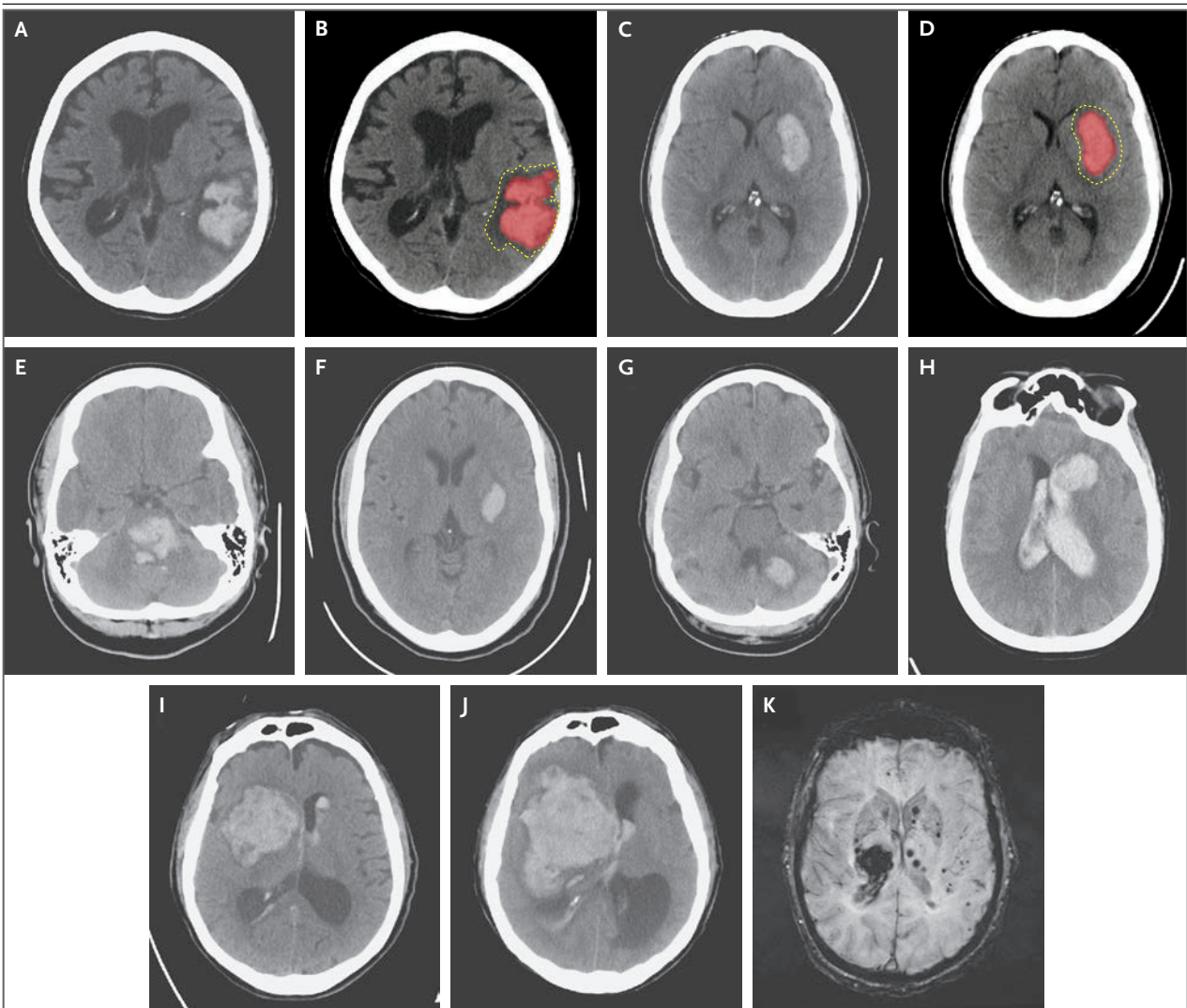


Figure 1. Spontaneous Intracerebral Hemorrhage.

Shown are intracerebral hemorrhages as seen on noncontrast computed tomography (Panels A through J) and on magnetic resonance imaging (Panel K). Lobar intracerebral hemorrhage (Panels A and B) and putaminal intracerebral hemorrhage (Panels C and D) are shown with a rim of perihematomal edema surrounding the intracerebral hemorrhage (outlined by dotted lines in Panels B and D). Other panels depict a pontine intracerebral hemorrhage in the middle portion of the brain stem (Panel E); basal ganglia intracerebral hemorrhage (Panel F); intracerebral hemorrhage in the left cerebellum (Panel G); frontal intracerebral hemorrhage with extension into the ventricles (compartments that contain cerebrospinal fluid), often referred to as an intraventricular hemorrhage (Panel H); an initial intracerebral hemorrhage that originated in the basal ganglia but underwent considerable expansion of the hematoma in the first hours after presentation (Panels I and J); and an intracerebral hemorrhage in the right thalamus (Panel K), with cerebral microbleeds in the juxtacortical or lobar locations that are often seen on susceptibility or gradient-echo sequences and that are typical of cerebrovascular amyloid.

HEMATOMA EXPANSION

Expansion of a hematoma causes tissue destruction beyond that caused by the initial clot. This type of damage, which is not always present, is apparent on serial imaging as mentioned, and typically occurs in the first 6 hours after the onset of symptoms. Several hemostatic treatments have

been tested to limit ongoing bleeding. In the Factor Seven for Acute Hemorrhagic Stroke (FAST) trial,²⁵ patients were randomly assigned to receive one of two dose levels of recombinant factor VIIa or placebo within 4 hours after the onset of symptoms of intracerebral hemorrhage. The increase in clot size at 24 hours was 15 percentage

points less in the group that received the highest dose of factor VIIa; however, there was no difference between the patient groups in the incidence of severe disability or death. The recently initiated FASTEST trial (NCT03496883) is testing treatment with factor VIIa to limit the expansion of a hematoma when administered within 2 hours after the onset of symptoms.

Patients with intracerebral hemorrhage that is associated with anticoagulant use are at a risk for hemorrhage expansion, neurologic deterioration, and poor outcome that is three to six times as high as that in patients with intracerebral hemorrhage in the absence of anticoagulation.²⁶ In a trial of patients with intracerebral hemorrhage who had received vitamin K antagonists and who had an international normalized ratio (INR) that was greater than 1.9, four-factor prothrombin complex concentrate was found to be superior to fresh frozen plasma for normalizing the INR and reducing the incidence of hematoma expansion.²⁷ Guidelines recommend intravenous vitamin K and prothrombin complex concentrate over fresh frozen plasma if the INR is elevated owing to the use of vitamin K antagonists.²² The reversal agents idarucizumab and andexanet alfa are available for use in the treatment of patients with intracerebral hemorrhage that is associated with direct oral anticoagulants in the form of direct thrombin and factor Xa inhibitors; however, clinical trials are needed to determine their effect, and it has been suggested that prothrombin complex concentrate can be substituted if reversal agents are not available.²²

To inform the treatment of patients with intracerebral hemorrhage associated with antiplatelet agents, patients in the Platelet Transfusion versus Standard Care after Acute Stroke due to Spontaneous Cerebral Haemorrhage Associated with Antiplatelet Therapy (PATCH) trial were randomly assigned to a group that received platelet transfusions or to a control group.²⁸ The group that received transfusions had twice the mortality and higher rates of disability than those in the group that did not receive transfusions. As a consequence, American Heart Association guidelines suggest that platelet transfusions should be withheld except in patients receiving aspirin therapy who have intracerebral hemorrhage and undergo neurosurgical procedures.²²

Two trials have tested the hypothesis that lowering of blood pressure would improve clinical

outcomes in patients with intracerebral hemorrhage. In the Antihypertensive Treatment of Acute Cerebral Hemorrhage II (ATACH-2) trial, 1000 patients with supratentorial intracerebral hemorrhage were randomly assigned to receive parenteral nicardipine to maintain a target range for systolic blood pressure of 110 to 139 mm Hg (intensive treatment) or to a target range of 140 to 180 mm Hg (standard treatment) for 24 hours.²⁹ Clinical outcomes were similar in the two groups at 90 days. In the Intensive Blood Pressure Reduction in Acute Cerebral Hemorrhage Trial 2 (INTERACT2),³⁰ 2783 patients were randomly assigned to the same blood-pressure target ranges as were those patients in the ATACH-2 trial, but INTERACT2 investigators extended the intervention for 7 days and left the selection of antihypertensive medication to the treating clinicians. The INTERACT2 trial findings were neutral with regard to the primary end point of death or severe disability at 90 days. Some patients in the intensive-treatment group in the ATACH-2 trial had acute kidney injury. After these trials, uncertainty remained about the ideal blood-pressure target, choice of medication and mode of administration, and duration of treatment. However, it may be reasonable to aim for an intensive strategy of lowering the patient's systolic blood pressure to 130 to 150 mm Hg, particularly if the systolic blood pressure exceeds 220 mm Hg within 2 hours after intracerebral hemorrhage. Close monitoring of kidney function and volume status is advised.

INTRAVENTRICULAR HEMORRHAGE

Intraventricular hemorrhage occurs in 30 to 50% of patients with intracerebral hemorrhage, and the resultant hydrocephalus owing to the added volume to the ventricular space, obstruction of cerebrospinal fluid (CSF) flow, and inflammation-stimulated secretion of CSF leads to a decreased level of arousal and poor outcome.³¹ Hydrocephalus that results in decreased wakefulness usually is treated by the placement of an external ventricular drain to divert CSF and reduce intracranial pressure. In the Clot Lysis Evaluation of Accelerated Resolution of Intraventricular Hemorrhage (CLEAR III) trial, which evaluated 500 patients with hydrocephalus after intracerebral hemorrhage, intraventricular administration of alteplase was used to dissolve the ventricular clot.³² Although the overall comparison between

groups showed no difference in functional outcomes, thrombolysis might have been associated with improved survival.³³ Patients who survive intraventricular hemorrhage typically have substantial disability at 6 months.

MASS EFFECT

The most severe consequence of the mass effect of an intracerebral clot and surrounding edema is transtentorial herniation. Studies have shown that surgical removal of the clot, undertaken in an attempt to alleviate transtentorial herniation, has had inconsistent or generally negative results. These findings have led to variations in practice with regard to the performance of craniotomy for clot removal. The Surgical Trial in Intracerebral Hemorrhage II (STICH II) trial examined the role of early clot-removal surgery in 601 patients with intracerebral hemorrhage; the results showed that the incidence of unfavorable outcome was similar in operated and conservative-treatment groups but suggested that the removal of lobar clots located within 1 cm of the cortical surface might have been beneficial.³⁴

Randomized trials are not available to gauge the effect of surgical treatment for cerebellar intracerebral hemorrhage. However, on the basis of large observational studies, the general practice has been to remove the clot if clinical or imaging signs of brain-stem compression are present or if the clot volume is greater than 15 ml.³⁵ Cerebellar hemorrhage commonly causes obstruction of the fourth ventricle that leads to hydrocephalus, which requires placement of an external ventricular drain.

Osmotherapy is typically used to treat acute neurologic deterioration that is secondary to the mass effect or edema associated with intracerebral hemorrhage, but the results have been uncertain. Raised intracranial pressure is usually treated with mannitol or a bolus of hypertonic saline.³⁶ Data are lacking to support prophylactic infusion of hypertonic saline or administration of glucocorticoids for conditions caused by the mass effect of an intracerebral hemorrhage.

INTENSIVE CARE AND WITHDRAWAL OF LIFE-SUSTAINING TREATMENT

Despite the inherent appeal of admitting patients with cerebral hemorrhage to an ICU, whether in-

tensive monitoring improves clinical outcome in intracerebral hemorrhage is not clear, and a trial to test this question seems unlikely to be conducted. Seizures after intracerebral hemorrhage can occur, although the role of prophylactic anti-seizure drugs in patients with intracerebral hemorrhage is unclear.³⁷ In patients with a depressed level of consciousness after intracerebral hemorrhage, continuous electroencephalography may detect inapparent seizures that require the initiation of antiseizure drugs.³⁸ Routine care in the intensive care unit includes airway protection and adequate pulmonary gas exchange for mitigation of secondary brain injury from hypoxemia, but the effectiveness of these measures is difficult to prove. Assessment of swallowing, maintenance of normothermia and normal glucose levels, and prophylaxis for deep-vein thrombosis (a therapy that is considered to be safe despite the presence of intracerebral hemorrhage) reduce additional morbidity.

Systems for early prognostication may not have adequate predictive ability to direct the withdrawal of life-sustaining treatments after intracerebral hemorrhage.³⁹ Patients who might otherwise have survived may succumb if life-sustaining treatments are withdrawn too early.⁴⁰ Several studies suggest that withholding the determination of prognosis in the first few days after hemorrhage is appropriate, and these findings are consistent with American Heart Association guidelines.^{22,41} Shared decision making to gauge the previously expressed wishes of the patient and family is a fruitful approach.

SECONDARY PREVENTION AND RESUMPTION OF ANTICOAGULANTS

Fewer than half the patients who survive intracerebral hemorrhage have adequate blood pressure control after discharge. Poorly controlled blood pressure is associated with adverse events such as recurrent stroke and death and is more common among Black persons than among non-Black persons.⁴² In addition to recurrent intracerebral hemorrhage, survivors are at risk for thrombotic events both in the brain and in the cardiovascular system.⁴³ The REstart or STop Antithrombotics Randomised Trial (RESTART) showed that antiplatelet therapy was unlikely to increase the risk of recurrence for survivors of

intracerebral hemorrhage associated with anti-thrombotic agents.⁴⁴ On the basis of these data, resumption of antiplatelet therapy may be reasonable for the prevention of thromboembolic events.

Among patients with intracerebral hemorrhage and atrial fibrillation, the safety of either starting or resuming anticoagulation remains unclear. In the phase 2 Apixaban after Anticoagulation-associated Intracerebral Hemorrhage in Patients with Atrial Fibrillation (APACHE-AF) trial, a slightly higher percentage of patients assigned to receive apixaban had nonfatal stroke or vascular death than patients assigned to avoid anticoagulation (26% vs. 24%).⁴⁵ The Start or Stop Anticoagulants Randomised Trial (SoSTART) showed that 8% of the patients assigned to start anticoagulation therapy had recurrence of intracerebral hemorrhage, as compared with 4% of the patients who did not start anticoagulation therapy, which did not provide evidence of noninferiority of starting anticoagulation during the first 2 years after intracerebral hemorrhage.⁴⁶ The above-mentioned phase 3 trials (ASPIRE and ENRICH-AF) to assess the effects of factor Xa inhibitors (e.g., apixaban) as compared with aspirin in patients with atrial fibrillation and intracerebral hemorrhage are currently enrolling participants. Observational and mendelian randomization studies have shown a

relationship between low levels of low-density lipoprotein cholesterol and the risk of intracerebral hemorrhage.⁴⁷ The Statins in Intracerebral Hemorrhage trial (SATURN, NCT03936361) is evaluating the resumption of statin medications in patients with lobar intracerebral hemorrhage who are at risk for recurrence and vascular thrombotic events.

FUTURE DIRECTIONS

In addition to the ongoing trials mentioned, trials of minimally invasive surgical evacuation of clots (e.g., aspiration, stereotactic removal, and intraventricular thrombolysis) could determine whether these procedures are effective and whether outcomes can be improved according to the type and location of the clot. Strategies are needed to test antiinflammatory and neuroprotective therapies.

Organized systems of care for stroke and clinical trials may offer an improved outlook for patients. Recent small trials tentatively suggest that mobile stroke units that are designed for the treatment of ischemic stroke could also facilitate prehospital detection, triage, and management of intracerebral hemorrhage, but further studies are needed.⁴⁸

Disclosure forms provided by the author are available with the full text of this article at NEJM.org.

REFERENCES

1. Tsao CW, Aday AW, Almarazooq ZI, et al. Heart disease and stroke statistics — 2022 update: a report from the American Heart Association. *Circulation* 2022;145(8):e153-e639.
2. Cordonnier C, Demchuk A, Ziai W, Anderson CS. Intracerebral haemorrhage: current approaches to acute management. *Lancet* 2018;392:1257-68.
3. van Asch CJ, Luitse MJ, Rinkel GJ, van der Tweel I, Algra A, Klijn CJ. Incidence, case fatality, and functional outcome of intracerebral haemorrhage over time, according to age, sex, and ethnic origin: a systematic review and meta-analysis. *Lancet Neurol* 2010;9:167-76.
4. Flaherty ML, Woo D, Haverbusch M, et al. Racial variations in location and risk of intracerebral hemorrhage. *Stroke* 2005;36:934-7.
5. O'Donnell MJ, Xavier D, Liu L, et al. Risk factors for ischaemic and intracerebral haemorrhagic stroke in 22 countries (the INTERSTROKE study): a case-control study. *Lancet* 2010;376:112-23.
6. PROGRESS Collaborative Group. Randomised trial of a perindopril-based blood-pressure-lowering regimen among 6,105 individuals with previous stroke or transient ischaemic attack. *Lancet* 2001;358:1033-41.
7. The SPS3 Study Group. Blood-pressure targets in patients with recent lacunar stroke: the SPS3 randomised trial. *Lancet* 2013;382:507-15.
8. Falcone GJ, Biffi A, Devan WJ, et al. Burden of risk alleles for hypertension increases risk of intracerebral hemorrhage. *Stroke* 2012;43:2877-83.
9. Fisher CM. Pathological observations in hypertensive cerebral hemorrhage. *J Neuropathol Exp Neurol* 1971;30:536-50.
10. Biffi A, Anderson CD, Battley TW, et al. Association between blood pressure control and risk of recurrent intracerebral hemorrhage. *JAMA* 2015;314:904-12.
11. Pasi M, Pongpitakmetha T, Charidimou A, et al. Cerebellar microbleed distribution patterns and cerebral amyloid angiopathy. *Stroke* 2019;50:1727-33.
12. Itoh Y, Yamada M, Hayakawa M, Ootomo E, Miyatake T. Cerebral amyloid angiopathy: a significant cause of cerebellar as well as lobar cerebral hemorrhage in the elderly. *J Neurol Sci* 1993;116:135-41.
13. Biffi A, Sonni A, Anderson CD, et al. Variants at APOE influence risk of deep and lobar intracerebral hemorrhage. *Ann Neurol* 2010;68:934-43.
14. Charidimou A, Imaizumi T, Moulin S, et al. Brain hemorrhage recurrence, small vessel disease type, and cerebral microbleeds: a meta-analysis. *Neurology* 2017;89:820-9.
15. Charidimou A, Meegahage R, Fox Z, et al. Enlarged perivascular spaces as a marker of underlying arteriopathy in intracerebral haemorrhage: a multicentre MRI cohort study. *J Neurol Neurosurg Psychiatry* 2013;84:624-9.
16. Woo D, Comeau ME, Venema SU, et al. Risk factors associated with mortality and neurologic disability after intracerebral hemorrhage in a racially and ethnically diverse cohort. *JAMA Netw Open* 2022;5(3):e221103.
17. Dowlatshahi D, Demchuk AM, Flaherty ML, Ali M, Lyden PL, Smith EE. Defining hematoma expansion in intracerebral hemorrhage: relationship with

- patient outcomes. *Neurology* 2011;76:1238-44.
18. Urday S, Kimberly WT, Beslow LA, et al. Targeting secondary injury in intracerebral haemorrhage — perihematomal oedema. *Nat Rev Neurol* 2015;11:111-22.
 19. Murthy SB, Moradiya Y, Dawson J, Lees KR, Hanley DF, Ziai WC. Perihematomal edema and functional outcomes in intracerebral hemorrhage: influence of hematoma volume and location. *Stroke* 2015;46:3088-92.
 20. Urday S, Beslow LA, Dai F, et al. Rate of perihematomal edema expansion predicts outcome after intracerebral hemorrhage. *Crit Care Med* 2016;44:790-7.
 21. Kidwell CS, Chalela JA, Saver JL, et al. Comparison of MRI and CT for detection of acute intracerebral hemorrhage. *JAMA* 2004;292:1823-30.
 22. Greenberg SM, Ziai WC, Cordonnier C, et al. 2022 Guideline for the management of patients with spontaneous intracerebral hemorrhage: a guideline from the American Heart Association/American Stroke Association. *Stroke* 2022;53(7):e282-e361.
 23. Hemphill JC III, Bonovich DC, Besmertis L, Manley GT, Johnston SC. The ICH Score: a simple, reliable grading scale for intracerebral hemorrhage. *Stroke* 2001;32:891-7.
 24. Hemphill JC III, Farrant M, Neill TA Jr. Prospective validation of the ICH Score for 12-month functional outcome. *Neurology* 2009;73:1088-94.
 25. Mayer SA, Brun NC, Begtrup K, et al. Efficacy and safety of recombinant activated factor VII for acute intracerebral hemorrhage. *N Engl J Med* 2008;358:2127-37.
 26. Flibotte JJ, Hagan N, O'Donnell J, Greenberg SM, Rosand J. Warfarin, hematoma expansion, and outcome of intracerebral hemorrhage. *Neurology* 2004;63:1059-64.
 27. Steiner T, Poli S, Griebel M, et al. Fresh frozen plasma versus prothrombin complex concentrate in patients with intracranial haemorrhage related to vitamin K antagonists (INCH): a randomised trial. *Lancet Neurol* 2016;15:566-73.
 28. Baharoglu MI, Cordonnier C, Al-Shahi Salman R, et al. Platelet transfusion versus standard care after acute stroke due to spontaneous cerebral haemorrhage associated with antiplatelet therapy (PATCH): a randomised, open-label, phase 3 trial. *Lancet* 2016;387:2605-13.
 29. Qureshi AI, Palesch YY, Barsan WG, et al. Intensive blood-pressure lowering in patients with acute cerebral hemorrhage. *N Engl J Med* 2016;375:1033-43.
 30. Anderson CS, Heeley E, Huang Y, et al. Rapid blood-pressure lowering in patients with acute intracerebral hemorrhage. *N Engl J Med* 2013;368:2355-65.
 31. Karim JK, Zhang J, Kurland DB, et al. Inflammation-dependent cerebrospinal fluid hypersecretion by the choroid plexus epithelium in posthemorrhagic hydrocephalus. *Nat Med* 2017;23:997-1003.
 32. Hanley DF, Lane K, McBee N, et al. Thrombolytic removal of intraventricular haemorrhage in treatment of severe stroke: results of the randomised, multicentre, multiregion, placebo-controlled CLEAR III trial. *Lancet* 2017;389:603-11.
 33. Kuramatsu JB, Gerner ST, Ziai WC, et al. Association of intraventricular fibrinolysis with clinical outcomes in ICH: an individual participant data meta-analysis. *Stroke* 2022 May 6 (Epub ahead of print).
 34. Mendelow AD, Gregson BA, Rowan EN, Murray GD, Gholkar A, Mitchell PM. Early surgery versus initial conservative treatment in patients with spontaneous supratentorial lobar intracerebral haematomas (STICH II): a randomised trial. *Lancet* 2013;382:397-408.
 35. Kuramatsu JB, Biffi A, Gerner ST, et al. Association of surgical hematoma evacuation vs conservative treatment with functional outcome in patients with cerebellar intracerebral hemorrhage. *JAMA* 2019;322:1392-403.
 36. Ropper AH. Hyperosmolar therapy for raised intracranial pressure. *N Engl J Med* 2012;367:746-52.
 37. Gilmore EJ, Maciel CB, Hirsch LJ, Sheth KN. Review of the utility of prophylactic anticonvulsant use in critically ill patients with intracerebral hemorrhage. *Stroke* 2016;47:2666-72.
 38. Vespa PM, O'Phelan K, Shah M, et al. Acute seizures after intracerebral hemorrhage: a factor in progressive midline shift and outcome. *Neurology* 2003;60:1441-6.
 39. Hwang DY, Dell CA, Sparks MJ, et al. Clinician judgment vs formal scales for predicting intracerebral hemorrhage outcomes. *Neurology* 2016;86:126-33.
 40. Becker KJ, Baxter AB, Cohen WA, et al. Withdrawal of support in intracerebral hemorrhage may lead to self-fulfilling prophecies. *Neurology* 2001;56:766-72.
 41. Morgenstern LB, Zahuranec DB, Sanchez BN, et al. Full medical support for intracerebral hemorrhage. *Neurology* 2015;84:1739-44.
 42. Biffi A, Teo K-C, Castello JP, et al. Impact of Uncontrolled Hypertension at 3 Months After Intracerebral Hemorrhage. *J Am Heart Assoc* 2021;10(11):e020392.
 43. Murthy SB, Zhang C, Diaz I, et al. Association between intracerebral hemorrhage and subsequent arterial ischemic events in participants from 4 population-based cohort studies. *JAMA Neurol* 2021;78:809-16.
 44. RESTART Collaboration. Effects of antiplatelet therapy after stroke due to intracerebral haemorrhage (RESTART): a randomised, open-label trial. *Lancet* 2019;393:2613-23.
 45. Schreuder FHBM, van Nieuwenhuizen KM, Hofmeijer J, et al. Apixaban versus no anticoagulation after anticoagulation-associated intracerebral haemorrhage in patients with atrial fibrillation in the Netherlands (APACHE-AF): a randomised, open-label, phase 2 trial. *Lancet Neurol* 2021;20:907-16.
 46. SoSTART Collaboration. Effects of oral anticoagulation for atrial fibrillation after spontaneous intracranial haemorrhage in the UK: a randomised, open-label, assessor-masked, pilot-phase, non-inferiority trial. *Lancet Neurol* 2021;20:842-53.
 47. Falcone GJ, Kirsch E, Acosta JN, et al. Genetically elevated LDL associates with lower risk of intracerebral hemorrhage. *Ann Neurol* 2020;88:56-66.
 48. Cooley SR, Zhao H, Campbell BCV, et al. Mobile stroke units facilitate prehospital management of intracerebral hemorrhage. *Stroke* 2021;52:3163-6.

Copyright © 2022 Massachusetts Medical Society.